

Oral implantology  
Case Presentation  
Case 1

# General Data

- Name:楊女士
- Gender:女
- Age:65
- Occupation:公
- Date of first visit:

# Chief Complaint

- 要求在上下顎缺牙區植牙。

# Present Illness

## 1、口內狀況 (圖1)

(1) 23 25 26 27 28 32 33 42 43 殘存牙齒

## 2、牙周狀況

(1) 三級搖動度：23 25 26 27 28 32 33 42 43

## 3、X-光判讀 (圖2)

(1) 嚴重牙周齒槽骨缺損吸收破壞：23 25 26 27 28 32 33 42 43

4、上顎兩側後牙區缺牙，經電腦斷層檢查發現上顎兩側後牙區上顎竇明顯氣化擴張，齒槽嵴距上顎竇底部僅1毫米(mm) available bone height 4 mm (圖3)

5、Non enough of bone height and width of upper ant residual ridge

# Personal history

- Personal habbies
  - Smoking(+)
  - Alcohol (-)
  - Betel quid(-)
  - Drug abuse (-)
  - Bruxism (-)

# Past medical history

# Past dental history

# Clinical Assessment



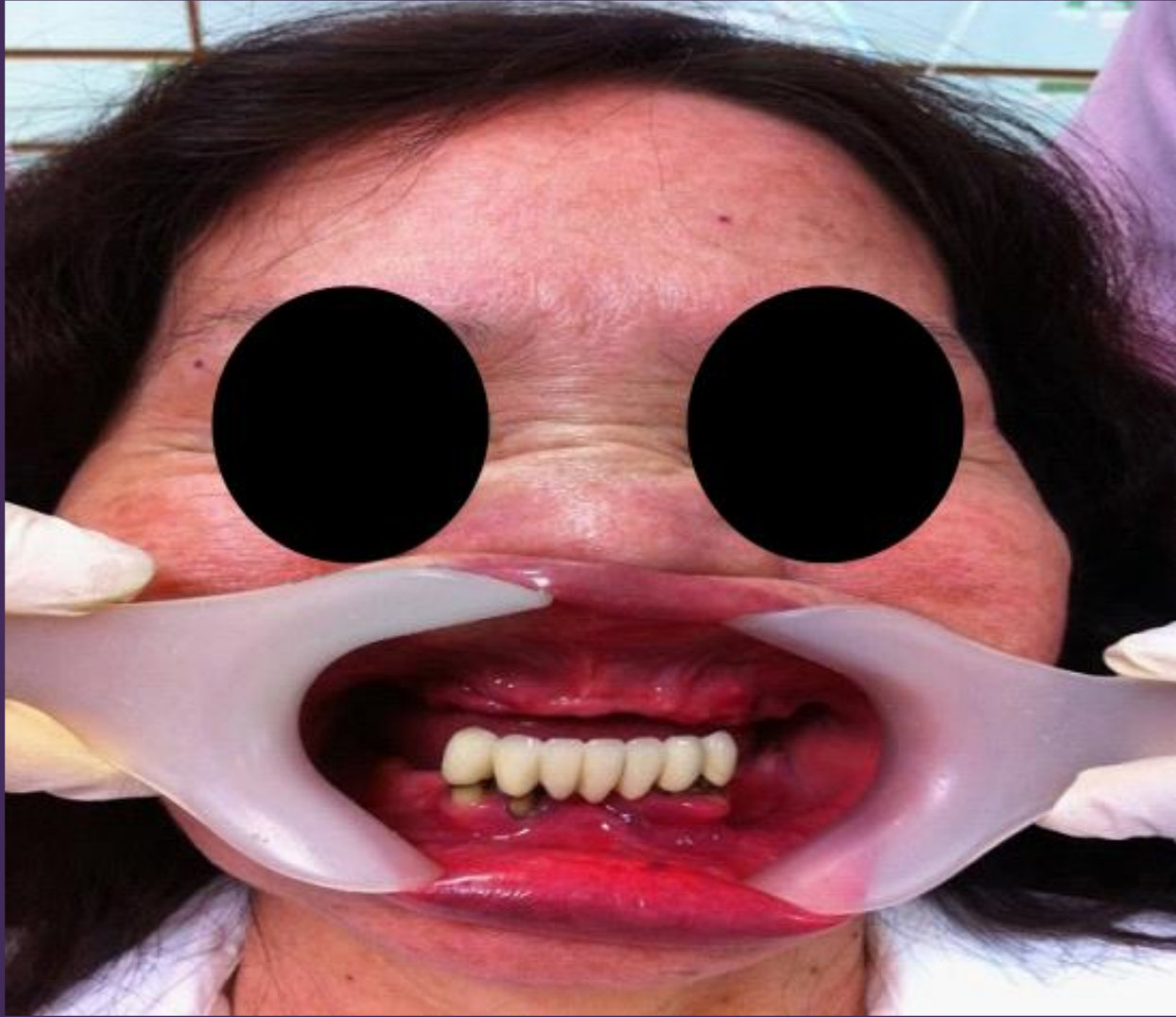

圖1.術前口內照

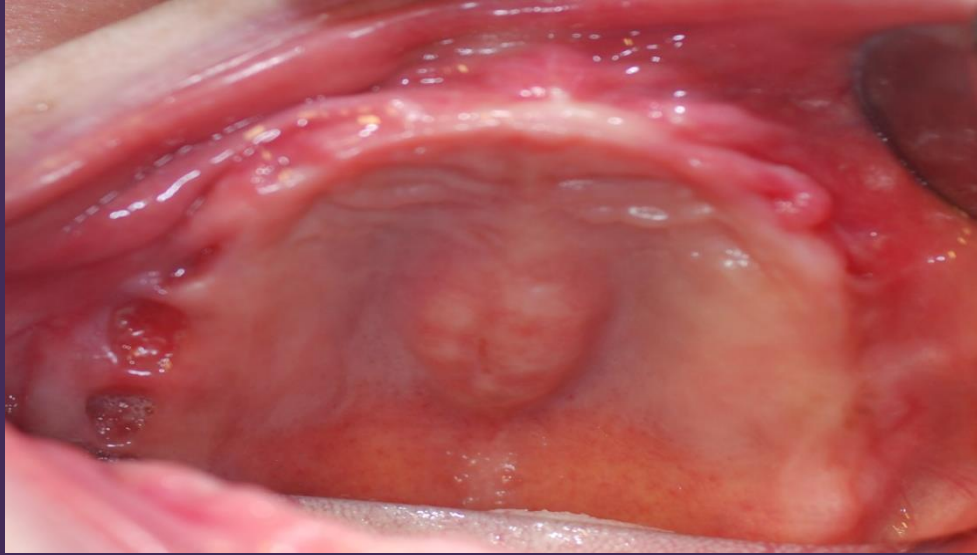


圖2術前上顎硬腭骨隆突  
(Torus palatinus)

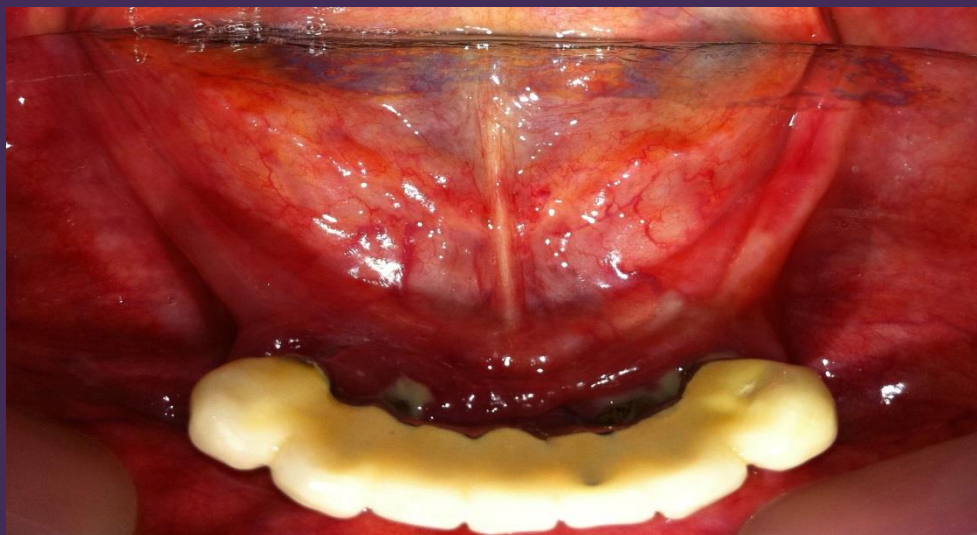

圖3 術前下顎口內照

# Radiographic Examination

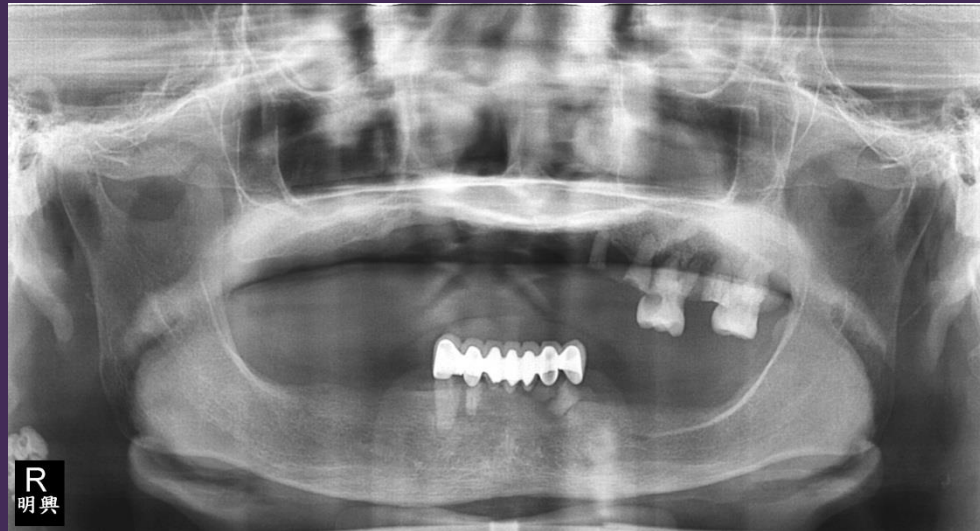


圖4 Non enough of bone height and width of upper ant residual ridge

# CBCCT Findings

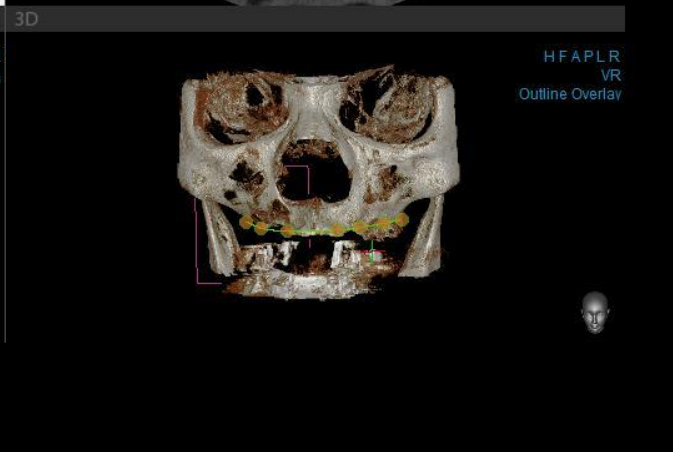
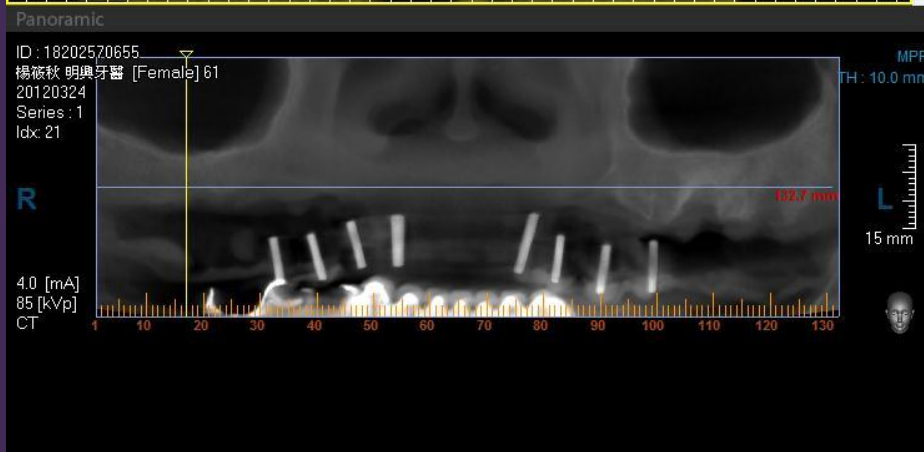
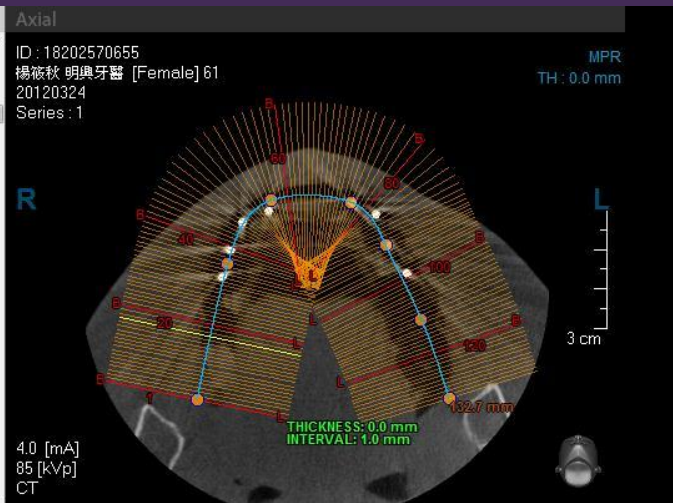
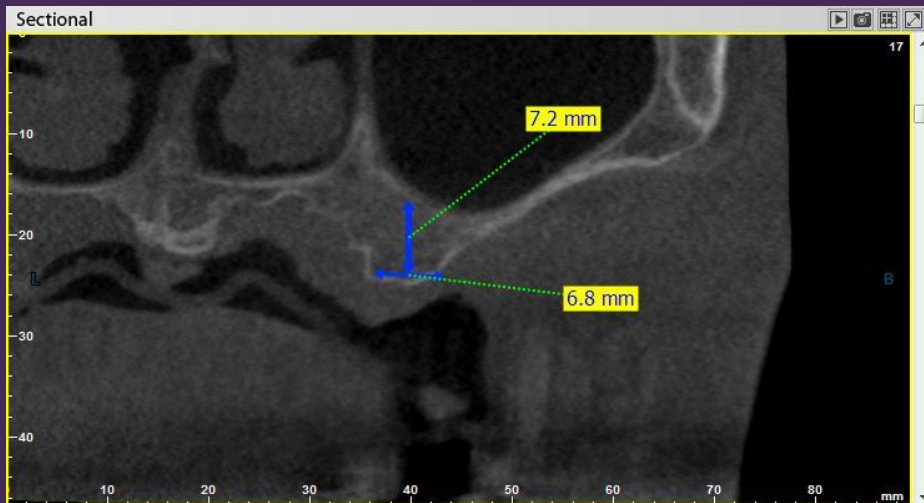


圖5術前所拍3D電腦斷層影像圖

# Occlusal analysis

- Type of occlusion.
- Occlusion scheme.
- Working contacts.
- Fremitus.



# Etiologic factors

# Problem List

# Diagnosis:

- 1、上顎兩側鼻竇下齒槽骨骨量不足，後牙無牙區齒槽骨萎縮高度不足。
- 2、全口多顆缺牙，23 25 26 27 28 32 33 42 43 重度牙周炎。
- 3、上顎前牙骨頭寬度高度皆不足

# Treatment plan

1、拔除預後不良的23 25 26 27 28 32 33 42 43

2、植牙贖復治療計劃

上下顎植體支持式贖復(Implant-supported Prosthesis)

(1)上顎植牙：11、13、14、15、16、17；23、24、25、26

\*Maxilla 14、missing available bone height 4 mm

\*上顎竇黏膜增厚

Tx. Plan: Maxilla 14、15、16

Vertical sandwich bone augmentation with bone graft for sinus lifting and staged implant

placement合併使用上顎竇增高術與 bone graft，後續於11、13、14、15、16、17；21、23、24、25、26,4個位置植入Osstem人工牙根並製作上顎全口植牙固定式瓷牙橋固定式義齒。

\*上顎全口植牙固定式瓷牙橋

以上植體分別支撐左右二段的牙橋，植體放置在左右兩側正中門牙、犬齒、第一及第二小齒處11、13、14、15、16、17；23、24、25、26分別以左右兩側各五支植體支撐兩個單位的牙橋。

\*下顎全口植牙植入8顆植體製作,固定式瓷牙橋

# Extraction/Socket management

# Stage I implant Placement

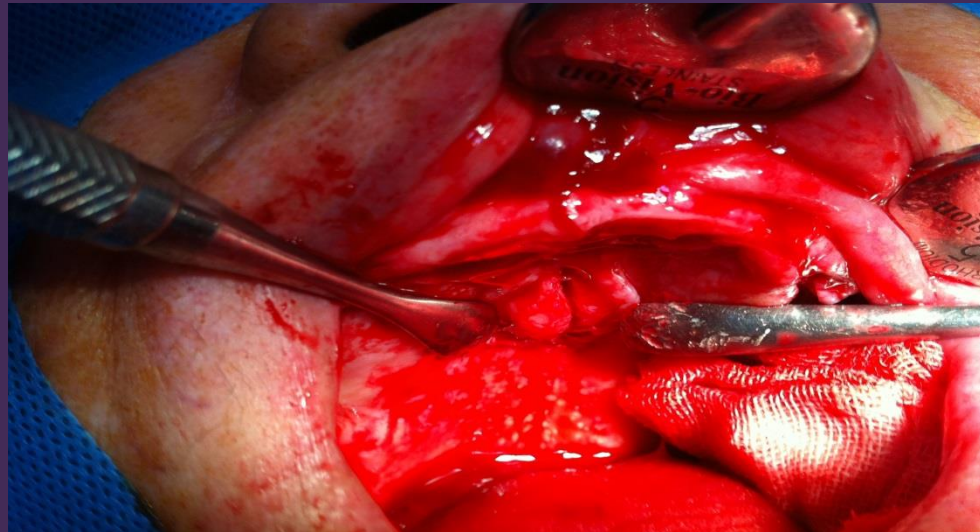


圖6以上顎腭骨隆突施行  
GBR bone graft

# Stage I implant Placement

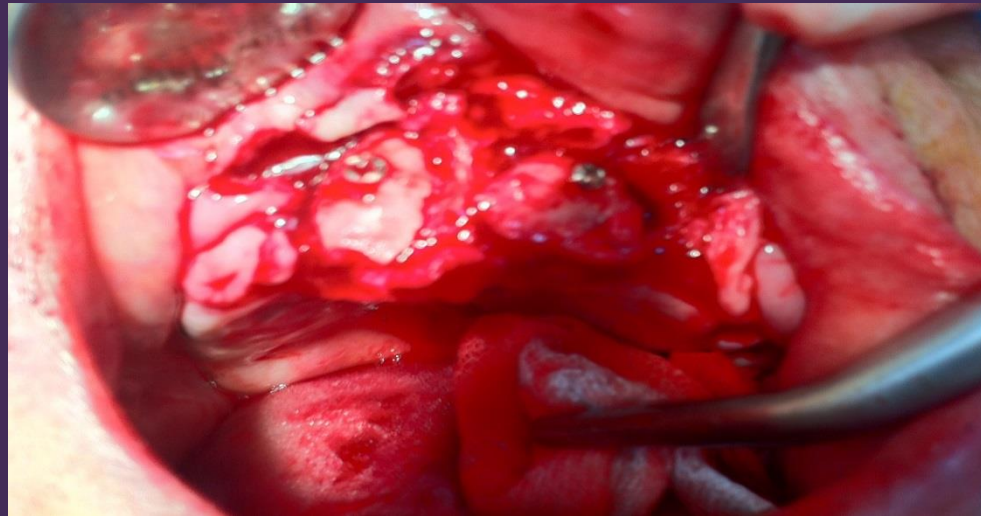


圖7以上顎腭骨隆突施行  
GBR bone graft

# Stage I implant Placement

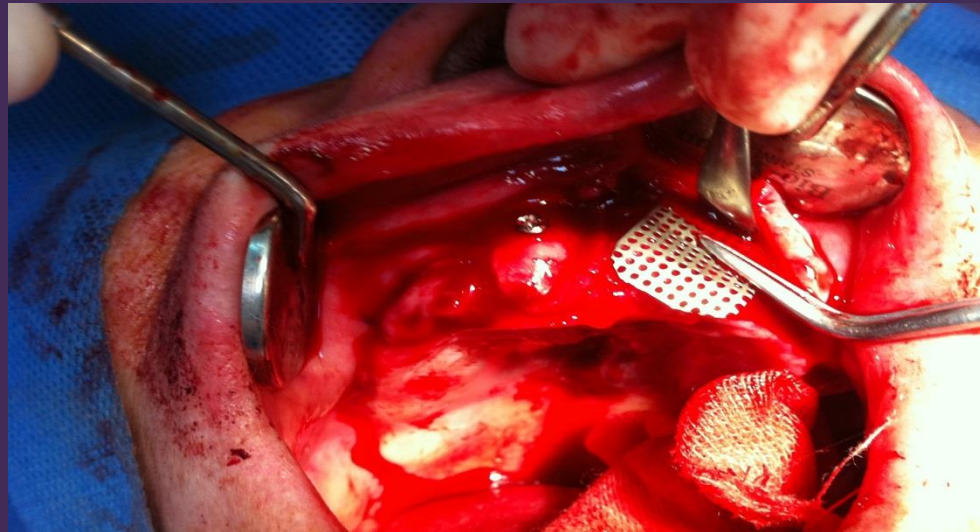


圖8以上顎腭骨隆突施行  
GBR bone graft



# Stage I implant Placement

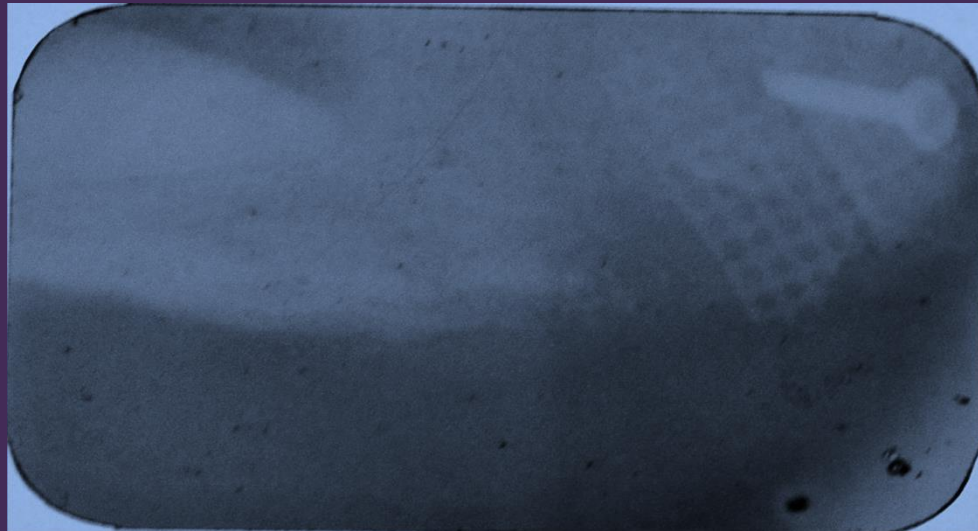


圖9 PAF上顎前牙11 bone  
screw fixation

# Stage I implant Placement

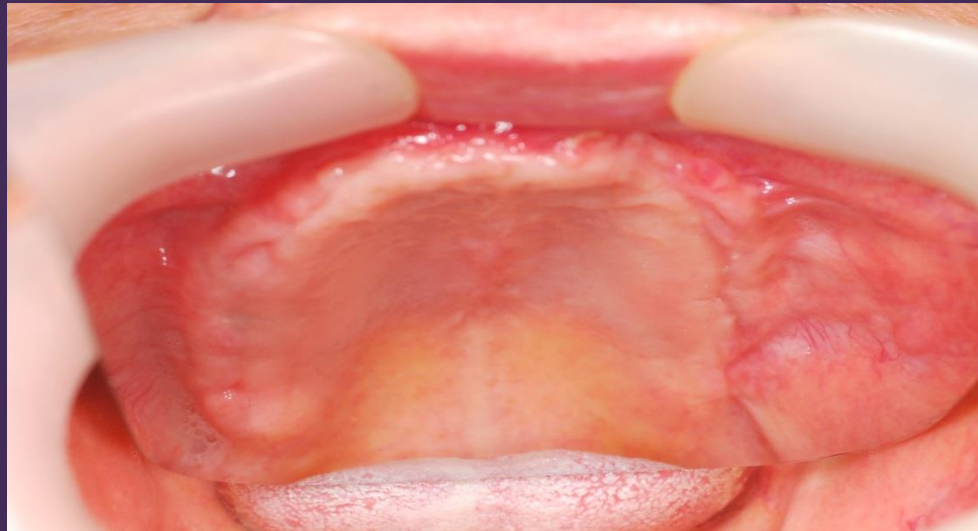

圖10上顎腭骨隆突手術修磨癒合情形

# Stage I implant Placement

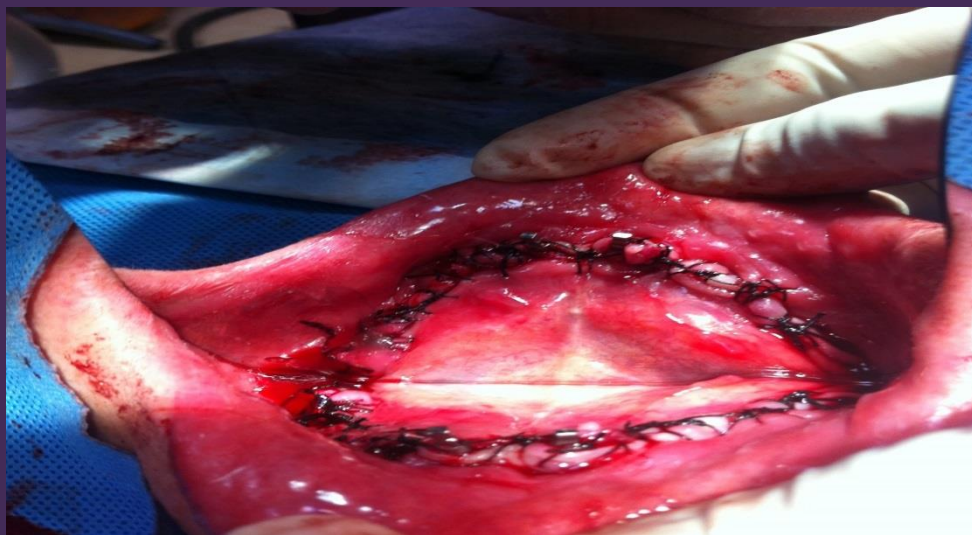

圖11下顎植入植體情形

# Stage II implant Placement 下顎

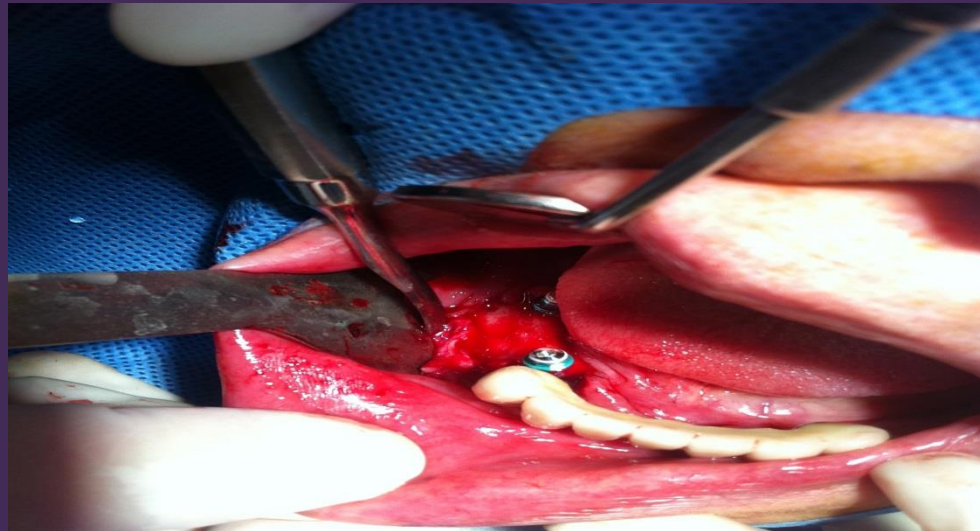


圖12下顎製作Provisional prothesis

# Stage I implant Placement 上顎

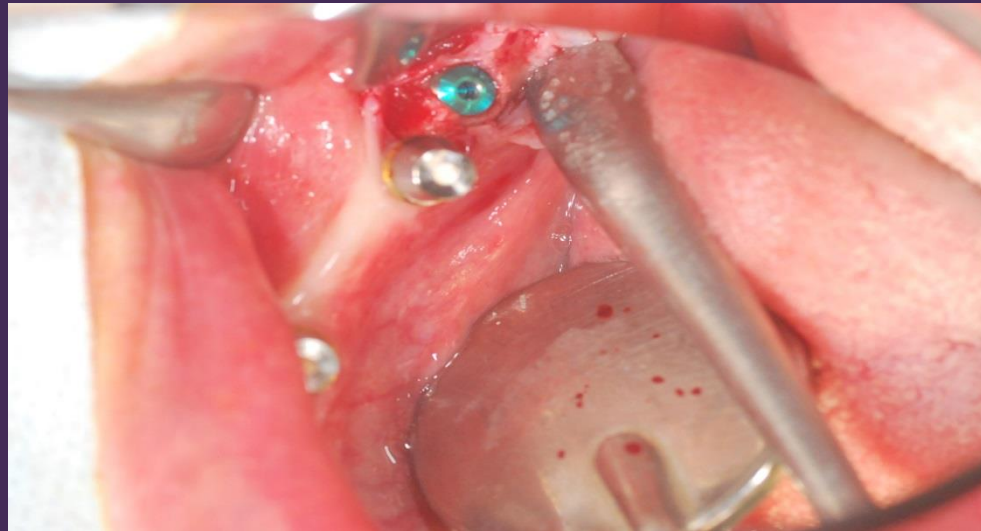


圖13 43、44、46植入植牙情形

# Stage II implant Placement 上顎

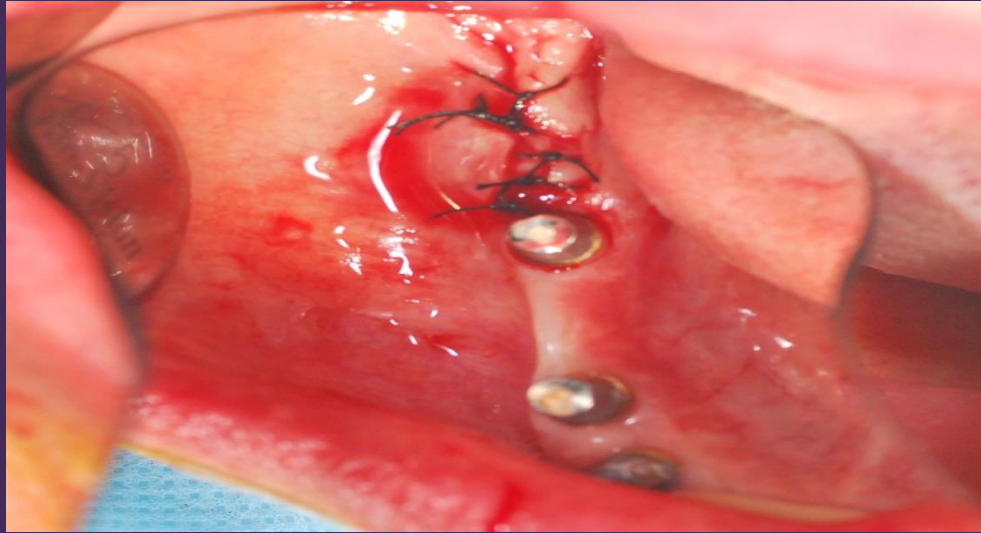


圖14 43、44、46接abutment情形

# Stage I implant Placement

## 下顎植入植體

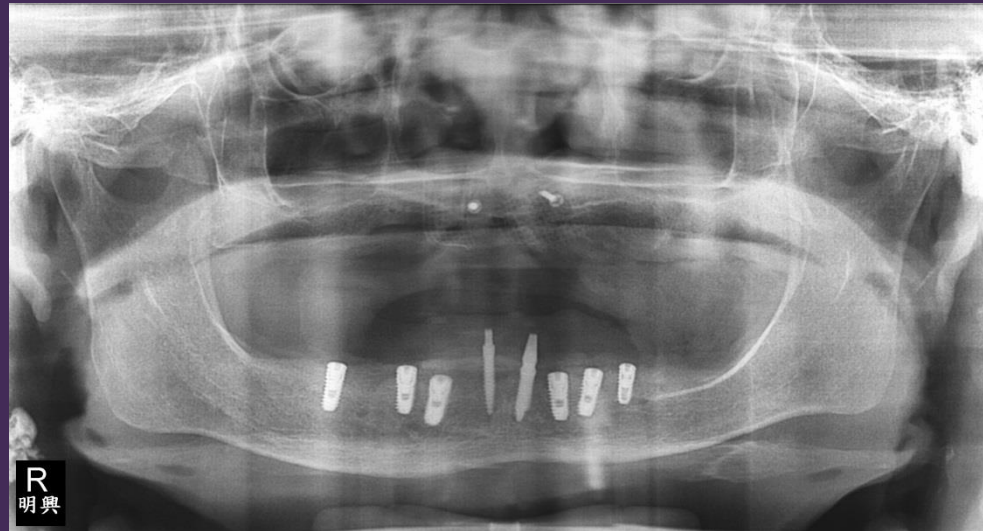


圖15 下顎植入植體情形

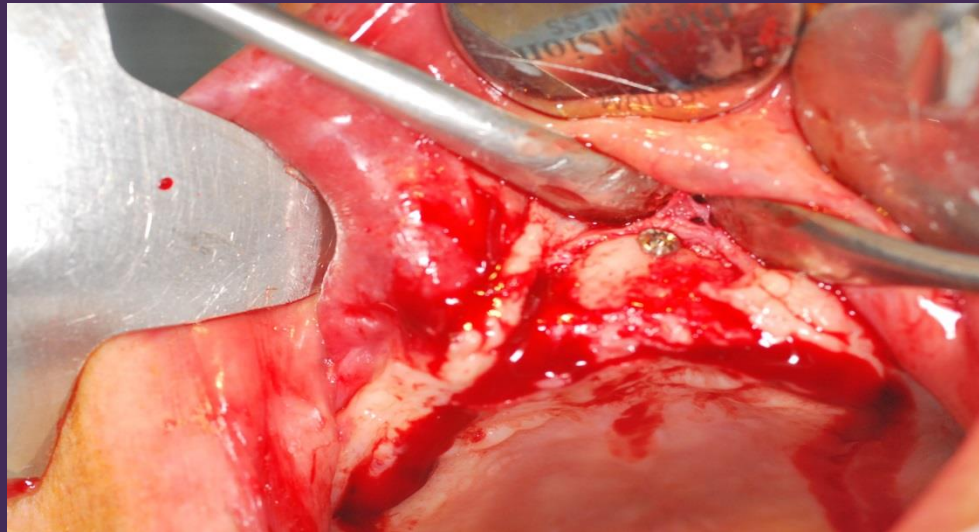


圖16上顎前牙11唇側with bone screw fixation



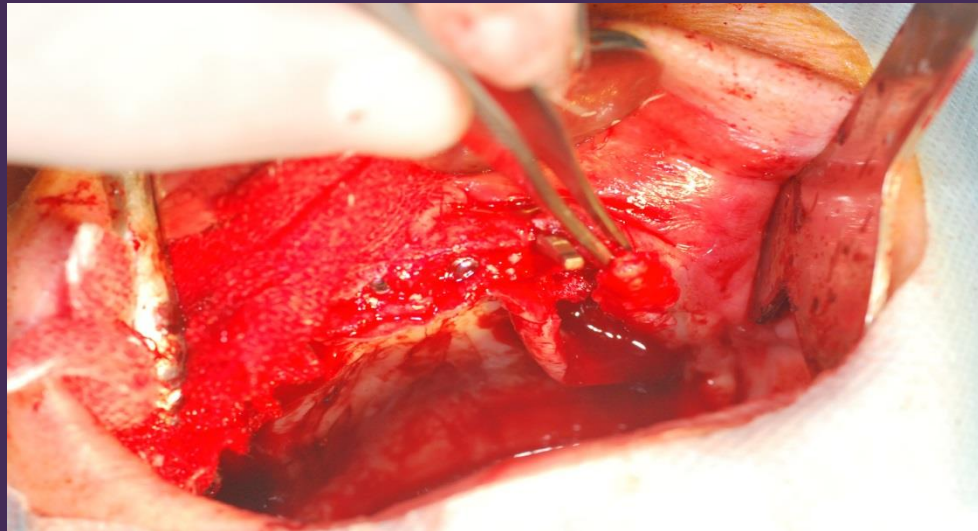


圖17 用上顎左上後牙區腭側結締組織移植  
SCTC

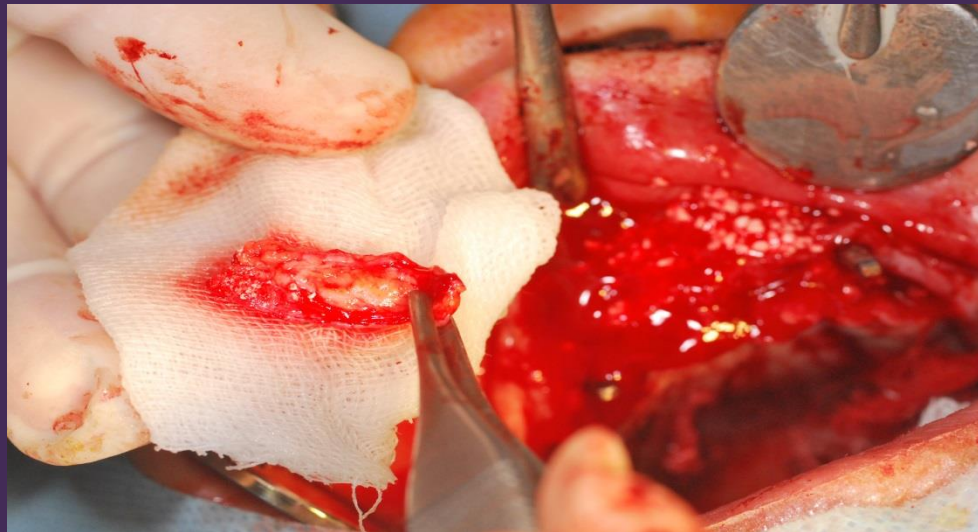


圖18 結締組織移植在接受處11的  
結締組織上

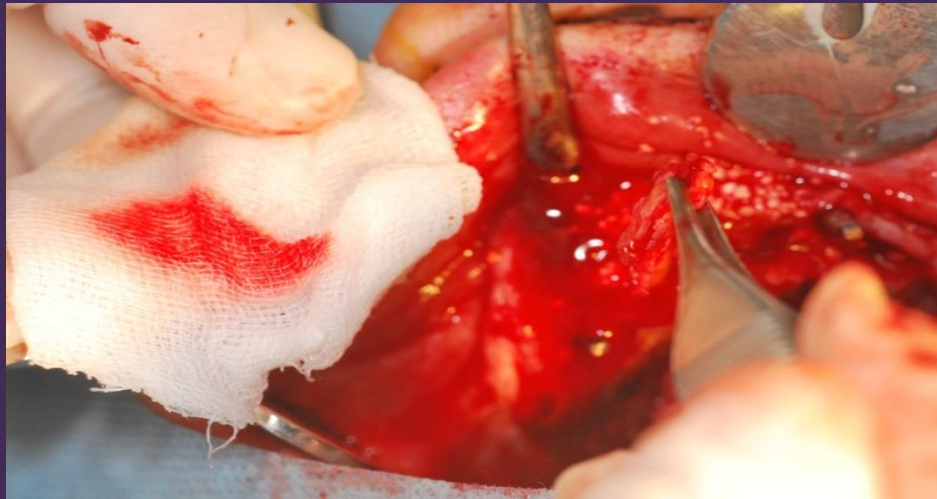


圖19 於右上11缺損處，利用12#刀片 prepare 一個partial thickness pocket，將取下來的 soft tissue 放入後縫合

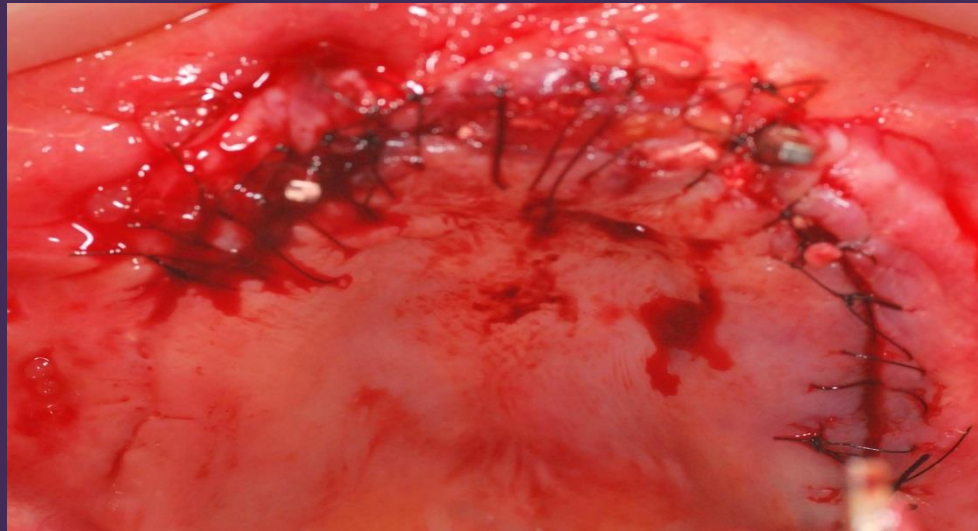


圖20 接受處11的唇側  
翻瓣冠向移位縫合

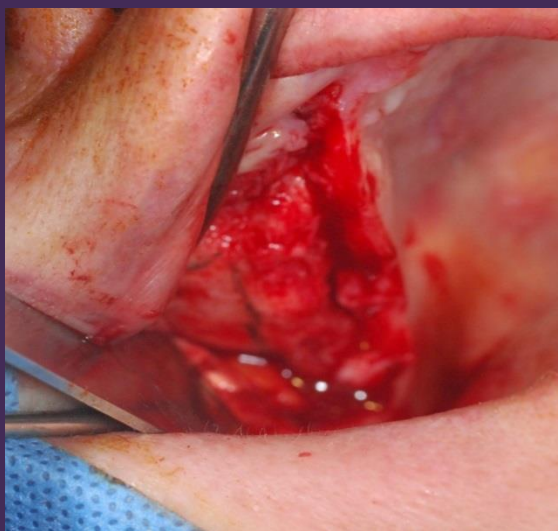


圖21 於14、15、16頰側處以超音  
波骨刀切開窗孔周緣

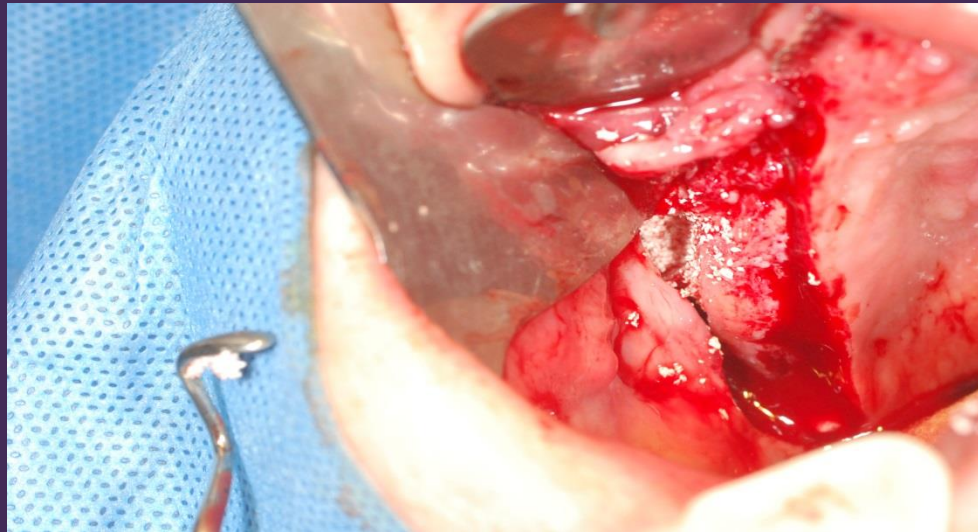


圖22 於14、15、16頰側處以超音  
波骨刀切開窗孔周緣

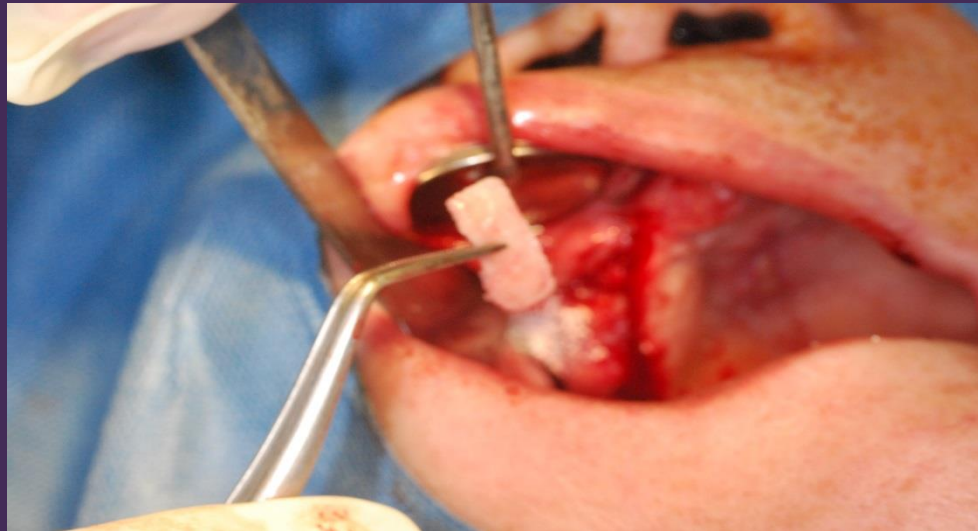


圖23 利用骨膜剝離子小心將窗孔骨片翻起移除

# Stage I implant Placement

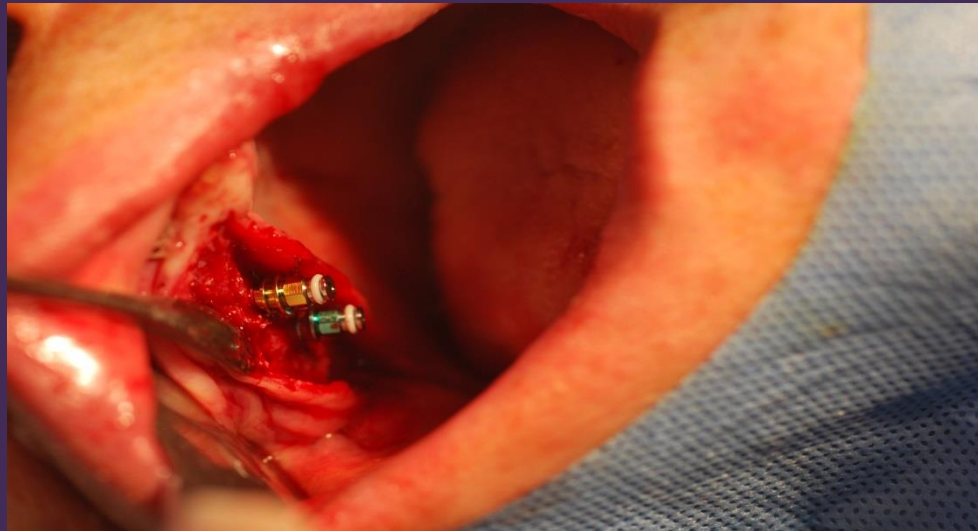


圖24竇膜下放入骨粉後,進行人工牙根種植,然後將窗口骨片在手術完成後蓋回原位固定。



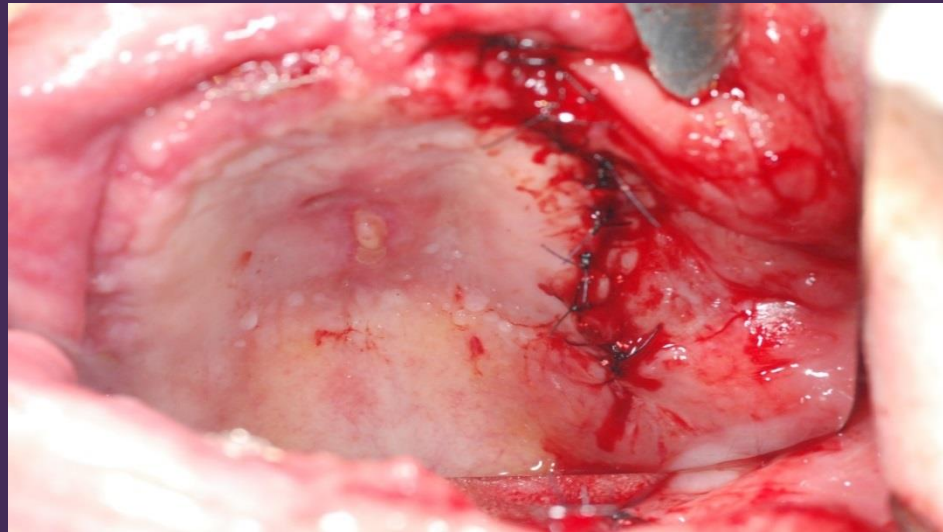


圖25 reposition和縫合

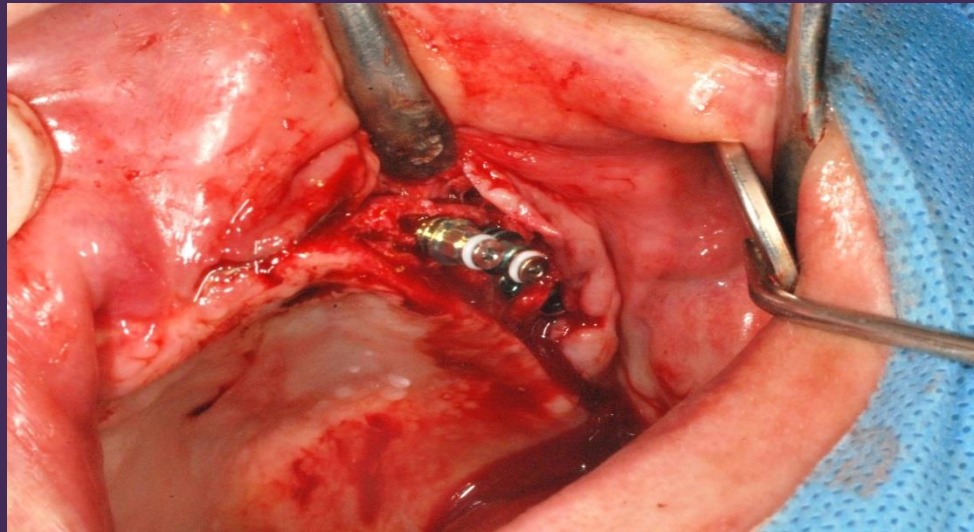


圖26 於24、25、26缺  
牙區植入植牙情形

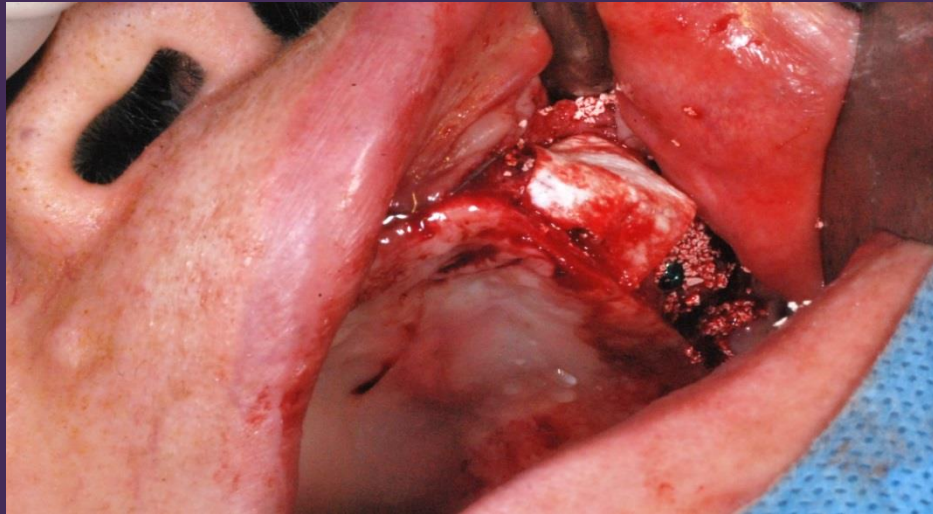


圖27於24、25、26區  
放置骨粉和再生膜

# Stage II implant Placement

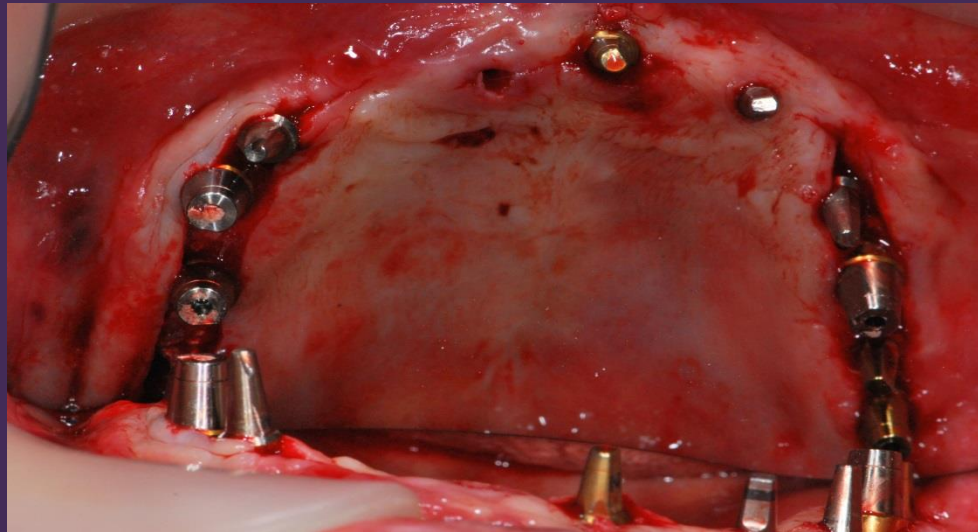


圖28上顎植牙區鎖上abutment

# Implant restoration

\*Final restoration

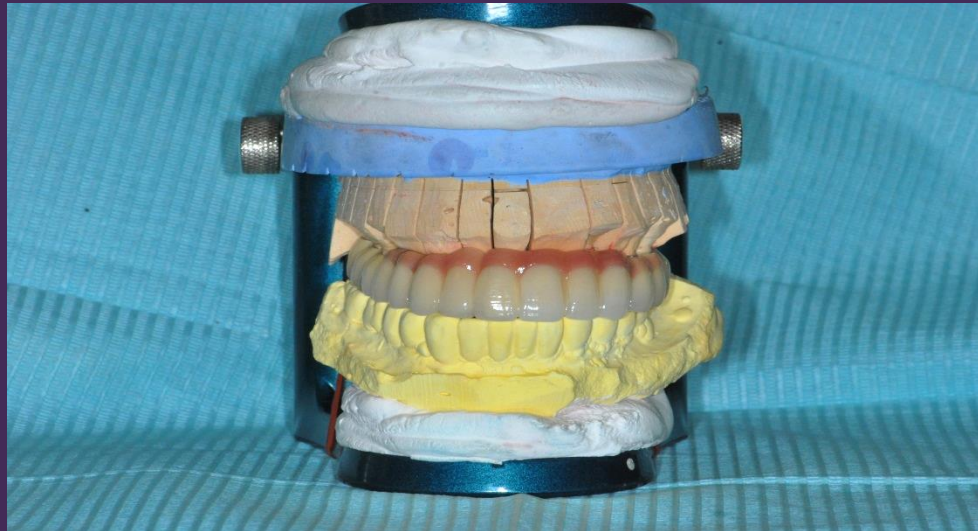

圖29 Determining the intermaxillary relationship. Mounting the models

# Implant restoration

\*Final restoration

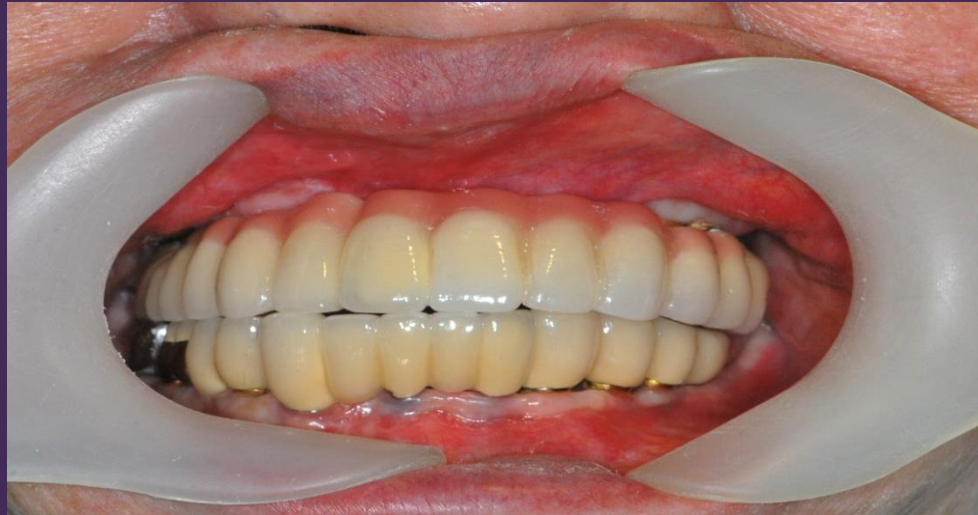

圖30 植牙贗復全口重建完成後的正面觀

# Implant restoration

\*Final restoration

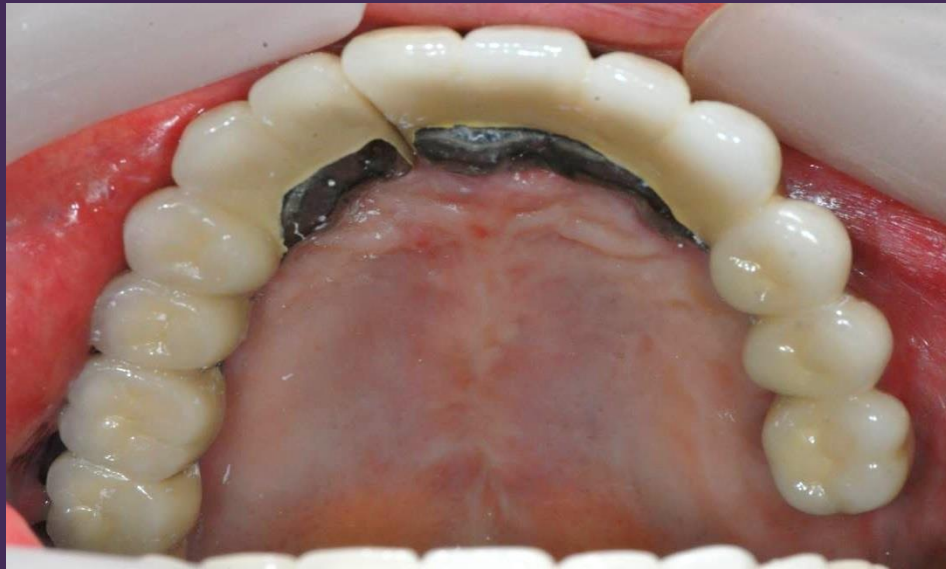

圖31 植牙贗復全口重建完成後  
的上顎咬合面觀

# Implant restoration

\*Final restoration

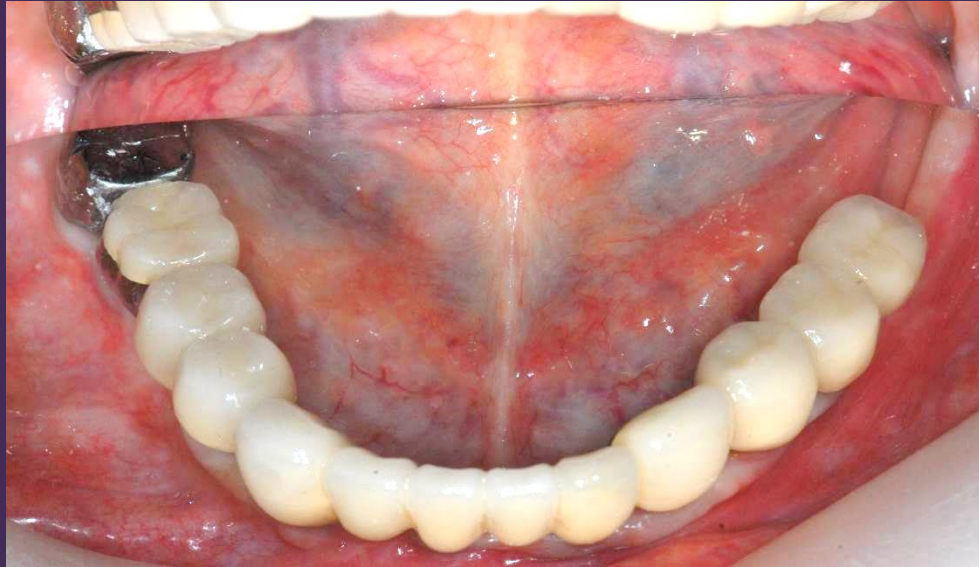


圖32 植牙贗復全口重建完成  
後的下顎咬合面觀



# Implant restoration

\*Final restoration

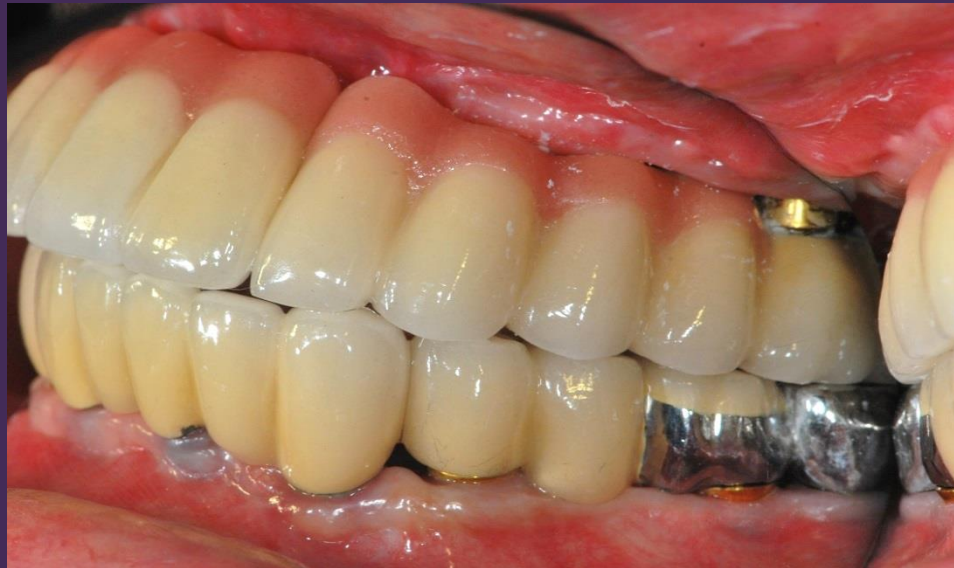

圖33 植牙贖復全口重建完成  
後的右側面觀

# Implant restoration

\*Final restoration

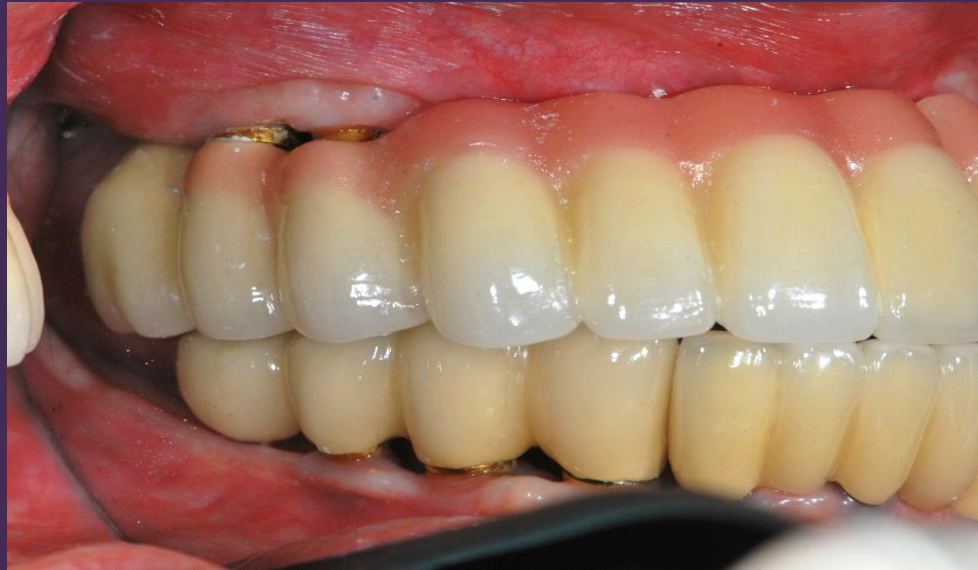

圖34 植牙贗復全口重建完成後的左側面觀

# Implant restoration

\*Final restoration

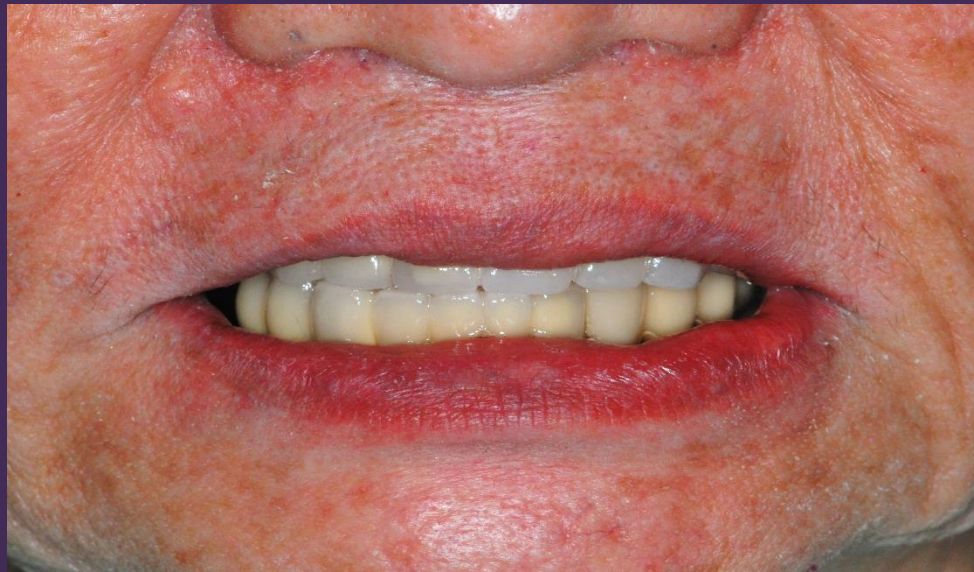

圖35 Extraoral photograph  
follow up

# Implant restoration

\*Final restoration

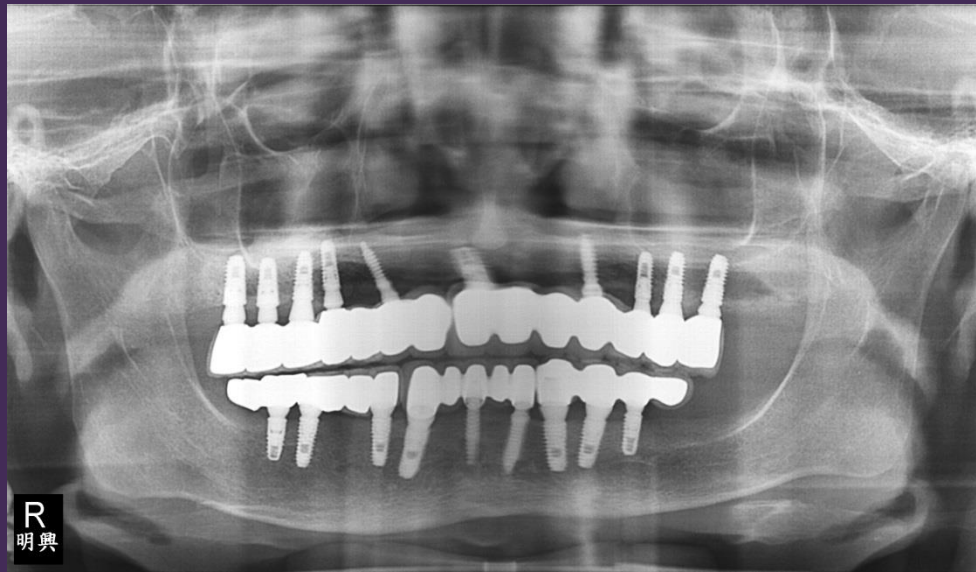


圖36 補綴治療全口重建完成環  
口X光片

# Maintenance Treatment



圖37 Extraoral photograph  
follow up

THANK YOU